

Research Paper

Roles of PCSK-9 on the Function of the Kidney in STZ Induced Diabetic Rats

Adunmo Godwin Olawoyin¹, Oyewopo Adeoye Oyetunji¹, Adeleke Opeyemi Samson², Oni Tolulope Ayodeji^{2*}, Akindehin Oluwatosin Abosede³ and Adeyemo Kareemat Adebanke²

¹University of Ilorin, Kwara State, Nigeria

²Osun State University, Osogbo, Osun State, Nigeria

³Trinity University, Yaba, Lagos State, Nigeria

Received : 2 January 2025

Revised : 10 February 2025

Accepted : 13 March 2025

***Corresponding Author Email:** tolulopeayodeji9@gmail.com

ABSTRACT

Background:

Diabetes Mellitus is a significant contributor to chronic renal disorders and end-stage kidney disease, causing extensive alterations in renal tissue. Studies have shown a complex relationship between plasma Proprotein Convertase Subtilisin/Kexin Type 9 (PCSK9) levels and diabetes, but the mechanisms of PCSK9 action remain unclear. This study aimed to investigate the impact of PCSK9 on kidney function in STZ-induced diabetic rats.

Methodology:

Twenty adult male Wistar rats (average weight 200 g) were randomly divided into four groups (five rats per group). Group A served as the control, Group B was induced with STZ (100 mg/kg) to establish diabetes, Group C received metformin (100 mg/kg), and Group D was treated with both metformin (100 mg/kg) and STZ (100 mg/kg). Metformin was administered orally, while STZ was given intraperitoneally.

Results:

Diabetes led to increased kidney marker enzyme levels, with AST and ALT significantly elevated, indicating renal damage in STZ-induced diabetic rats. GPx and GSH levels were also elevated, while MDA concentrations were higher in the diabetic control group compared to the metformin-treated group. Metformin significantly reduced most biomarkers, restoring them to levels close to those of the control group, demonstrating its protective effect. Watermelon seed oil contains some important pharmacological properties that offered some protection against cadmium-induced cerebellar neurotoxicity. Administration of this oil could ameliorate neurodegenerative diseases associated with free radical production.

Conclusion:

Histological and biochemical findings confirm metformin's ameliorative effect on kidney dysfunction, underscoring its renal protective role. Additionally, plasma PCSK9 levels are significantly higher in diabetic patients than in non-diabetic individuals, as observed in this and previous studies.

KEYWORDS: PCSK-9, Metformin, Stz, Diabetes.

INTRODUCTION

Diabetes mellitus is a state of physiological stress, during which homeostasis of carbohydrate and lipid metabolism is improperly regulated by the insulin, leading to the elevation in plasma glucose level. Among several endocrine disorders, diabetes mellitus is the supremely diagnosed endocrinopathies in humans and other household pets which can easily be induced in experimental animal models¹. Diabetes is characterized by hyperglycemia, because of β -cell dysfunction/resistance against insulin by the other peripheral cells of the body. Liver is one of the major metabolic regulatory organs involved in the biotransformation and detoxification of drugs, toxic chemicals. During such biotransformation in liver these insoluble molecules are made hydrophilic². In diabetes mellitus oxidative stress causes the breakdown of liver cells, which may lead leakage of proteins and other major constituents of cells into the blood stream. Altered glucose homeostatic balance can lead to adverse effects in the whole body of an organism.

The second vital organ kidney acts potentially to release glucose into the blood because gluconeogenesis occurs in this organ. It has the potential to release glucose into the blood. Kidney as the excretory and filtration unit of the body is highly exposed to the heavy free radical load and therefore may lead to various anomalies in the normal functioning of its own physiology³. Various literatures support heavy free radical production and physiological stress as a major causative agent for diabetes⁴. Such physiological stresses during diabetic condition may impair the renal functions due to hyperproduction of urea, uric acid and creatinine in blood which constitutes the basic parameters for renal function analysis⁵.

Diabetes has been reported to be the leading cause of kidney disease. About 1 out of 4 adults with diabetes has kidney disease⁶. High blood glucose, can damage the blood vessels in the kidneys. When the blood vessels are damaged, they don't work well i.e., they can't filter blood like they should, which can cause wastes to build up in the body. Having diabetes for a longer time increases the chances of kidney damage⁶.

Human PCSK9 gene, initially called as neural apoptosis-regulated convertase 1 (NARC-1), was discovered by Seidah *et al.* who reported identification of the ninth member of the mammalian proproteinconvertase family located in

chromosome 1p33–34.3 close to the third genetic locus associated with FH⁷. Several lines of experimental studies have revealed that liver is not only the key source of PCSK9 biosynthesis, but also the main target of PCSK9 activity⁶. It has been also shown that PCSK9 is synthesized in extra hepatic tissues such as kidney, small intestine, central nervous system, pancreas, colon epithelia, and vascular smooth muscle cells⁷.

Among the emerging factors implicated in diabetic complications is Proprotein Convertase Subtilisin/ Kexin Type 9 (PCSK9). PCSK9 is a serine protease that plays a pivotal role in cholesterol metabolism by regulating low-density lipoprotein receptor (LDLR) levels on the hepatocyte surface⁷. Beyond its well-established role in lipid regulation, PCSK9 has been increasingly linked to glucose metabolism, inflammation, and tissue remodeling, suggesting its potential involvement in diabetes-related complications, including kidney dysfunction⁸.

Another critical aspect of managing diabetes-related kidney dysfunction is the use of therapeutic agents, such as metformin. Metformin, an oral antihyperglycemic drug, is widely recognized as the first-line treatment for type 2 diabetes. It primarily exerts its effects by suppressing hepatic gluconeogenesis, enhancing insulin sensitivity, and promoting glucose uptake in peripheral tissue⁹. Beyond its glucose-lowering effects, metformin has been shown to possess anti-inflammatory, antioxidative, and antifibrotic properties, which may contribute to its protective effects on diabetic kidneys. Despite advances in our understanding of diabetic nephropathy and its management, significant gaps remain regarding the interplay between PCSK9 and metformin in the context of kidney dysfunction in diabetes. While several studies have explored the relationship between PCSK9 levels and diabetes, few have examined its direct impact on renal tissue and how therapeutic agents like metformin may modulate this effect. Given the increasing evidence linking PCSK9 to metabolic and inflammatory pathways, it is crucial to investigate its role in diabetic kidney disease to identify potential targets for intervention⁸. This study aimed to investigate the roles of PCSK9 in kidney dysfunction associated with STZ-induced diabetes and to assess the potential protective effects of metformin. By evaluating key biochemical markers, antioxidant enzyme activities, and histological changes in renal tissue.

MATERIALS AND METHODS

Procurement of Compounds and Animals

All compounds used (Streptozotocin and Metformin) were pure compounds procured from Akol pharmacy Osogbo. Experimental animals used for this research were procured from Bolamid Farms investment, Osogbo, Osun State. The animals were allowed access to food and water *ad libitum*. They were given two weeks to get used to the lab condition before the study started. The study followed the rules set by the Health Research Ethics Committee at the College of Health Sciences, Osun State University, Osogbo, Nigeria, and complied with the National Institute of Health guidelines for caring for and using lab animals.

Experimental Design

Twenty male (20) adult Wistar rats which average weight was 200g were used and the animals were randomly split into four groups (A, B, C and D), each with five rats. Group A (served as the control), Group B was induced with STZ (100 mg/kg), Group C received metformin (100 mg/kg), Group D was treated with both metformin (100 mg/kg) and STZ (100 mg/kg).

Ethical Concern

Study was conducted in accordance with best global practice for experimental assessments with ethical approval granted by the Institutional Ethical Committee for Animal Experimentation of ABU, Zaria with the approval reference ID: ABUCAUC/2012/087.

Sacrifice of Experimental Animals, Sample Collection and Hormonal Assay

Blood was withdrawn from the apex of the heart from the twenty adult rats, which were first anesthetized with 80 mg/kg of ketamine hydrochloride, 12 hours after the last administration. The blood was then dispensed into red-topped tubes for hormonal analysis. The kidney was excised following an abdominal incision, and they were fixed in Neutral buffer Formalin for histological analysis. It was then dehydrated progressively in stronger alcohols, cleared in Xylene and infiltrated in paraffin wax, before being embedded in molten paraffin wax. A rotary microtome was then used to slice the paraffin block containing the tissue into 4µm thick sections. The sections were then transferred to a glass slide, floated in a water bath set at 40 degrees Celsius, and stained with hematoxylin and eosin dyes.

Hormonal Assay

Serum samples were assayed for Insulin in batches with the control sera at both physiological and pathological levels by the standard Quantitative Enzyme-Linked Immunosorbent Assay (ELISA) technique with microwell kit which was manufactured by Syngened. The manufacturer instructions that accompanied the assay kits were strictly adhered to.

Measurement of Body Weight

The weights of the animals were obtained upon arrival and on weekly basis using digital weighing balance scale in order to account for possible results in physical changes in rats upon administration (STZ and chemical compounds) at regular intervals. The weights are checked for the comparison of possible changes from the initial weight and kept in record.

Statistical Analysis

The mean and standard error of mean (S.E.M) of the entire data was calculated. Comparison of means was made by one way analysis of variance (ANOVA) using Graphpad Prism 8. Tukey's test was used to adjust for multiple comparisons. P value < 0.05 was considered to be statistically significant.

RESULTS

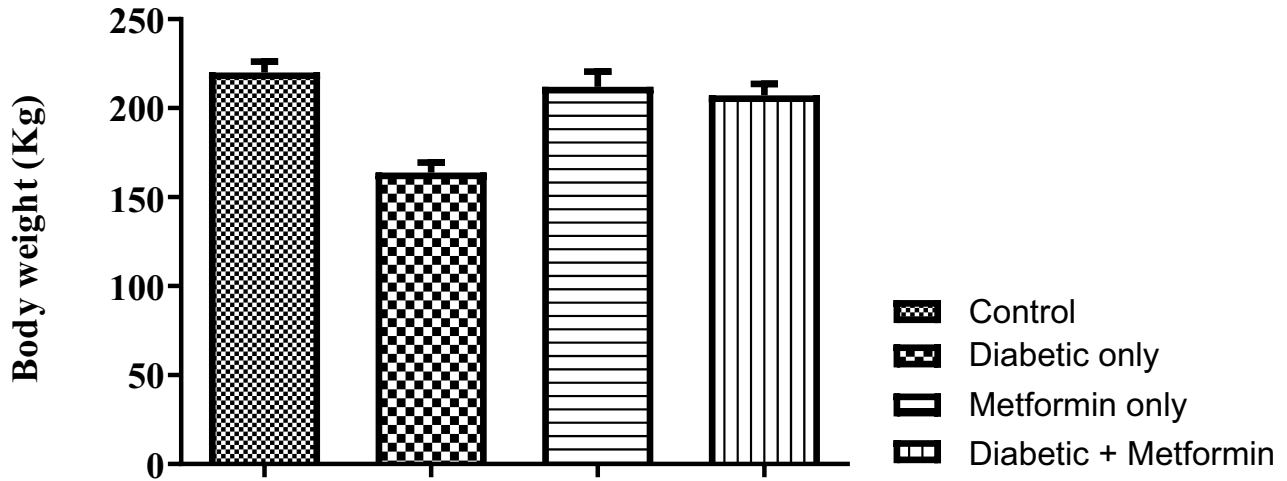


Figure 1: Average Body Weights of Rats across all Groups including Control, Diabetic only, Metformin only and Diabetic+Metformin

Graph depicting the body weight changes of the animals in each group. Data are presented as mean and standard error of mean (mean ±SEM). The post hoc analysis showed a significant difference among the control group and the treatment groups exposed to STZ, metformin, and the combination of both ($F(3,16) = 13.64, p < 0.0001$). Additionally, one way ANOVA indicated that there is no significant difference in the final body weight between the control group and the metformin group ($p = 0.8398$) and as well as the control and Diabetic+Metformin Group ($p = 0.5600$).




Figure 2: The Level of PCSK-9 across all Groups including Control, Diabetic only, Metformin only and Diabetic+Metformin

Data are presented as mean and standard error of mean (mean ±SEM). The post hoc analysis showed a significant difference among the control group and the treatment groups exposed to STZ, metformin, and the combination of both ($F(3,16) = 27.93, p < 0.0001$). Additionally, one way ANOVA indicated that there is no significant difference in the level of PCSK-9 between the control group and the metformin group ($p = 0.9991$) and as well as the control and Diabetic+Metformin Group ($p = 0.9693$).

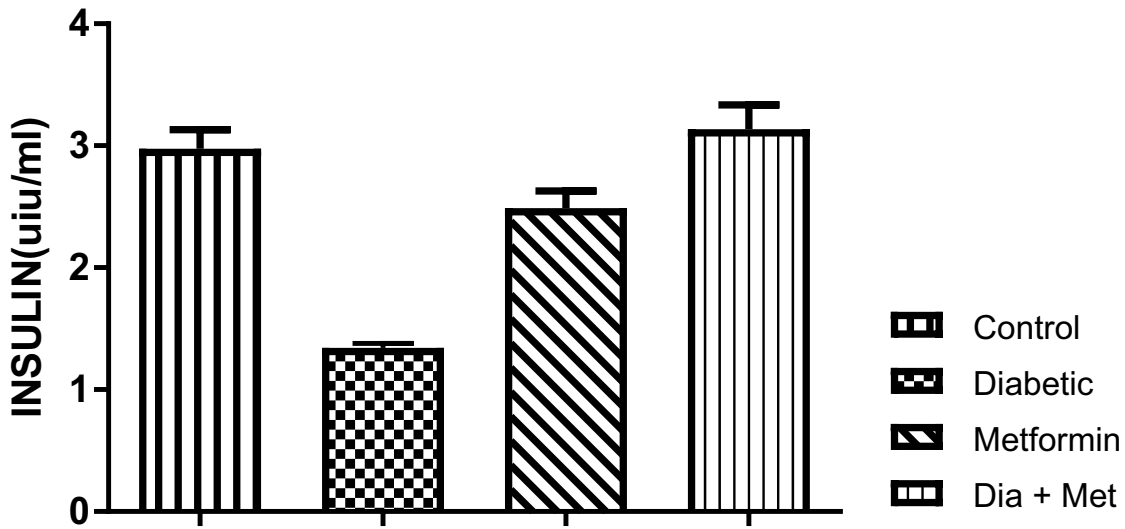


Figure 3: The Level of **Insulin** among all Groups including Control, Diabetic only, Metformin only and Diabetic+Metformin

Data are presented as mean and standard error of mean (mean \pm SEM). The post hoc analysis showed a significant difference among the control group and the treatment groups exposed to STZ, metformin, and the combination of both ($F(3,16) = 30.32$, $p < 0.0001$). Additionally, one way ANOVA indicated that there is no significant difference in the level of insulin between the control group and the metformin group ($p = 0.1295$) and as well as the control and Diabetic+Metformin Group ($p = 0.8677$).




Figure 4: The Level of **Malondialdehyde (MDA)** across all Groups including Control, Diabetic only, Metformin only and Diabetic+Metformin

Data are presented as mean and standard error of mean (mean \pm SEM). The post hoc analysis showed a significant difference among the control group and the treatment groups exposed to STZ, metformin, and the combination of both ($F(3,16) = 32.29$, $p < 0.0001$). Additionally, one way ANOVA indicated that there is no significant difference in the level of MDA between the control group and the metformin group ($p = 0.9894$).

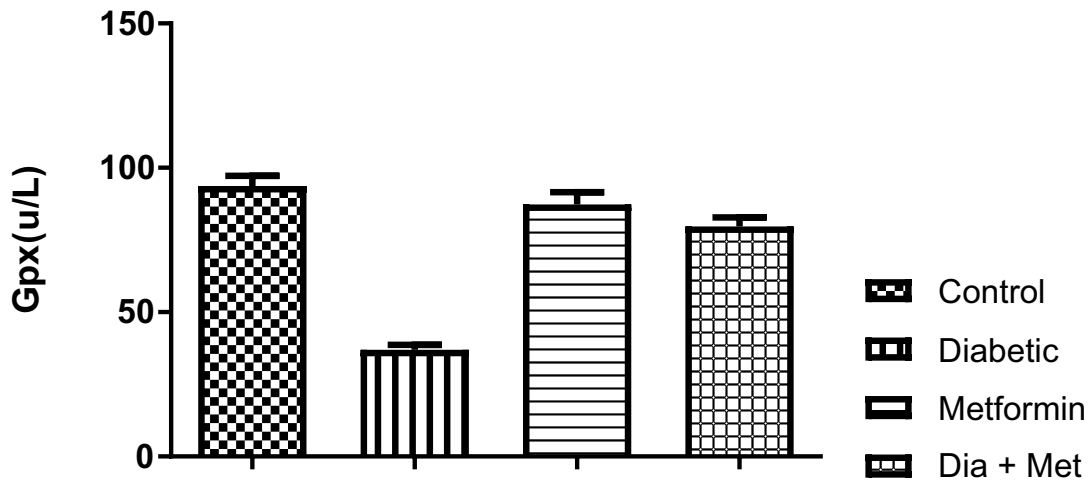


Figure 5: The Level of Glutathione Peroxidase (GPX) among all Groups including Control, Diabetic only, Metformin only and Diabetic+Metformin

Data are presented as mean and standard error of mean (mean±SEM). The post hoc analysis showed a significant difference among the control group and the treatment groups exposed to STZ, metformin, and the combination of both (F (3,16) =60.98, p<0.0001). Additionally, one way ANOVA indicated that there is no significant difference in the level of GPX between the control group and the metformin group (p=0.5476).




Figure 6: The Level of Aminotransferase (ALT) across all Groups including Control, Diabetic only, Metformin only and Diabetic+Metformin

Data are presented as mean and standard error of mean (mean ±SEM). The post hoc analysis showed a significant difference among the control group and the treatment groups exposed to STZ, metformin, and the combination of both (F (3,16) =160.98, p<0.0001). Additionally, one way ANOVA indicated that there is no significant difference in the level of ALT between the control group and the metformin group (p=0.9963).




Figure 7: The Level of Aspartate Aminotransferase (AST) across all Groups including Control, Diabetic only, Metformin only and Diabetic+Metformin

Data are presented as mean and standard error of mean (mean \pm SEM). The post hoc analysis showed a significant difference among the control group and the treatment groups exposed to STZ, metformin, and the combination of both ($F(3,16) = 407.9$, $p < 0.0001$). Additionally, one way ANOVA indicated that there is no significant difference in the level of AST between the control group and the metformin group ($p = 0.7898$).




Figure 8: The Level of Gamma-glutamyl transferase (GGT) across all Groups including Control, Diabetic only, Metformin only and Diabetic+Metformin

Data are presented as mean and standard error of mean (mean \pm SEM). The post hoc analysis showed a significant difference among the control group and the treatment groups exposed to STZ, metformin, and the combination of both ($F(3,16) = 1355$, $p < 0.0001$). Additionally, one way ANOVA indicated that there is no significant difference in the level of GGT between the control group and the metformin group ($p = 0.7724$).

HISTOLOGICAL RESULT

The histological analysis of kidney reveals the distal convoluted tubule, proximal convoluted tubule, the glomeruli and the Bowman's capsule. Normal renal morphology was seen in the control and majority of the metformin treated groups with normal cortex and medulla, well defined Bowman's capsule with the outer layer lined with simple squamous epithelium, the glomerulus looks as clusters of capillaries. Kidney cortices samples from the control group exhibited normal structure of three layer of filtration barrier, with normal glomerular basement membrane (GBM) thickness and equally distributed podocytes foot like structures. In the diabetic rats, there is cellular degeneration and multifocal fatty degeneration, the podocytes processes merged together in large

areas, and filtration barrier was blurry and no longer clearly distinguishable. Treatment with metformin ameliorated these ultra-structural changes in the kidneys of diabetic rats, Notably GBM thickening was significantly decreased in the metformin treated group. Metformin protects histopathological changes of the kidney as compared with the control group, model rats exhibited reduced glomerular tuft, increased bowman's spaces, vacuolar degeneration and dilated renal capsules and renal tubules. The section of the untreated diabetic group showed deformed renal corpuscles with atrophy of glomerular capillaries.

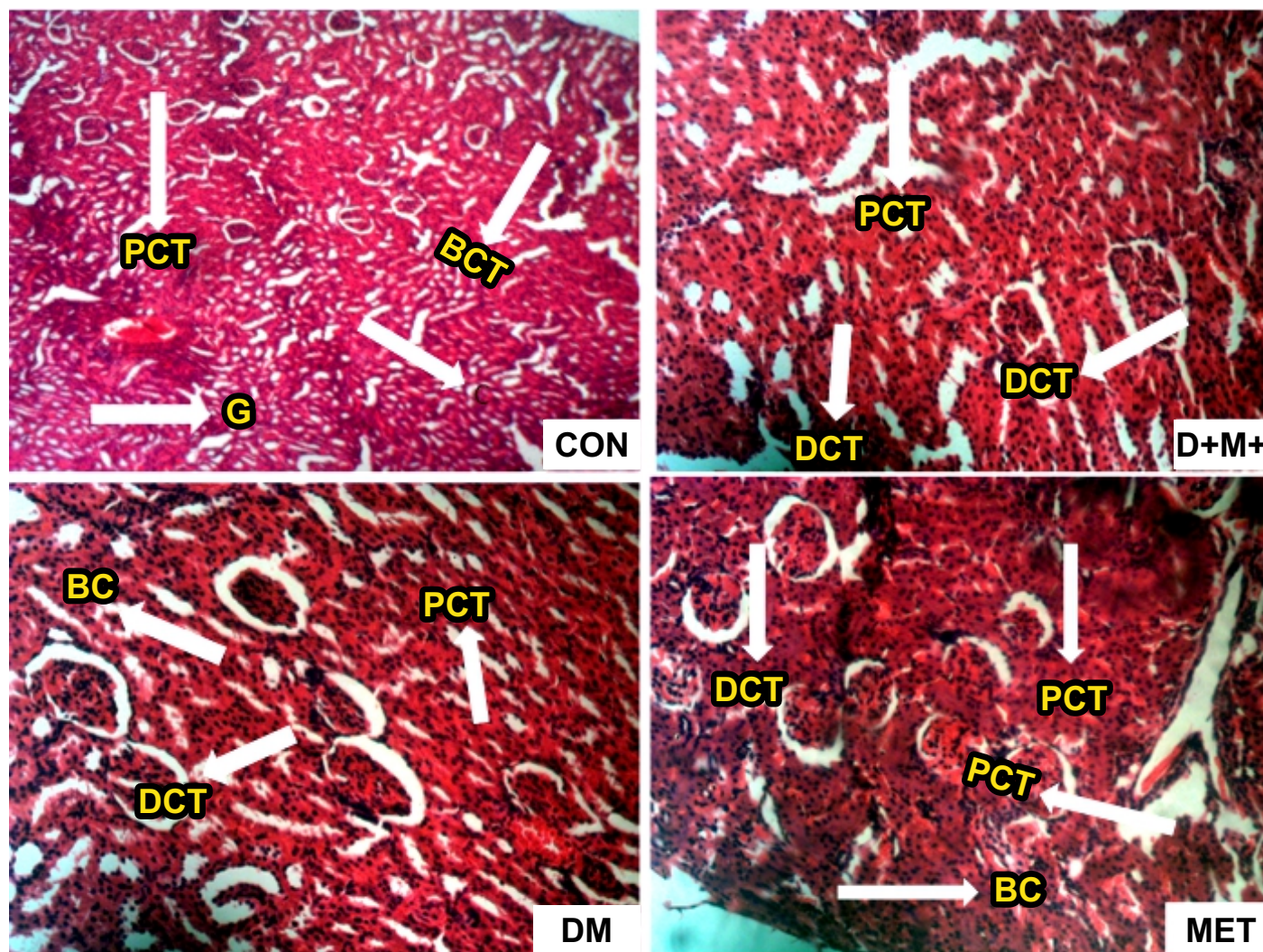


Figure 9: Photomicrograph of Histological Section of the Kidney across all Experimental Groups Stained with Hematoxylin and Eosin x200

Key: DCT: Distal Convoluted Tubule, PCT: Proximal Convoluted Tubule, BC: Bowman's capsule, G: Glomeruli, C: Capillaries

DISCUSSION

This study investigated the roles of Proprotein Convertase Subtilisin/ Kexin Type 9 (PCSK9) and metformin in kidney function in a Streptozotocin (STZ)-induced diabetic rat model. Diabetes Mellitus (DM) is known to significantly affect renal function, contributing to chronic kidney disease and end-stage kidney disease¹⁰. The results of this study align with previous findings, demonstrating that diabetes induces renal damage, as evidenced by elevated levels of key biomarkers such as AST, ALT, GPx, and GSH, alongside increased malondialdehyde (MDA) concentrations in diabetic rats.

The elevated levels of MDA observed in diabetic rats indicate increased oxidative stress, a hallmark of diabetic nephropathy¹¹. Oxidative stress plays a pivotal role in the progression of renal damage by promoting lipid peroxidation, inflammation, and fibrosis. Metformin administration significantly reduced MDA levels, suggesting its antioxidative properties, which have been previously reported to mitigate oxidative stress in diabetic models¹².

PCSK9 has emerged as a critical regulator of lipid metabolism and has been implicated in diabetes and its complications. Elevated plasma PCSK9 levels observed in diabetic conditions may exacerbate renal dysfunction through pathways involving inflammation and cholesterol metabolism⁸. This study supports these findings by demonstrating that PCSK9 levels are significantly higher in diabetic conditions.

The protective effects of metformin observed in this study highlight its multifaceted role beyond glucose-lowering. Metformin not only reduced oxidative stress but also restored the levels of key renal biomarkers to near-normal values. This aligns with existing literature emphasizing the anti-inflammatory and antifibrotic effects of metformin, which contribute to renal protection in diabetes⁹.

Histological findings further corroborated the biochemical results, with diabetic kidneys exhibiting significant structural damage, including glomerular hypertrophy and tubular degeneration. Metformin treatment ameliorated these changes, indicating its potential in preserving renal architecture. These results are consistent with previous studies demonstrating metformin's role in mitigating histopathological changes in diabetic nephropathy¹³.

CONCLUSION

This study highlights the critical roles of Proprotein Convertase Subtilisin/Kexin Type 9 (PCSK9) and metformin in the context of diabetic kidney dysfunction. Elevated PCSK9 levels in diabetes were associated with renal damage, oxidative stress, and altered biochemical markers. Metformin demonstrated significant protective effects by reducing oxidative stress, restoring renal biomarkers, and preserving kidney histology. These findings underscore metformin's potential beyond glucose regulation, emphasizing its role in mitigating diabetic nephropathy.

CONFLICT OF INTEREST : None

FINANCIAL SUPPORT : None

REFERENCES

- Catchpole B, Ristic JM, Fleeman LM, Davison LJ. Canine diabetes mellitus: Can old dogs teach us new tricks? *Diabetologia*. 2015; 48:1948–56.
- Gonzalez FJ. Role of cytochromes P450 in chemical toxicity and oxidative stress: Studies with CYP2E1. *Mutat Res*. 2015; 569:101–10.
- Nakhaee A, Bokaeian M, Saravani M, Farhangi A, Akbarzadeh A. Attenuation of oxidative stress in streptozotocin-induced diabetic rats by *Eucalyptus globulus*. *Indian J Clin Biochem*. 2013; 24:419–25.
- Ismail N, Becker B, Strzelczyk P, Ritz E. Renal disease and hypertension in non-insulin-dependent diabetes mellitus. *Kidney Int*. 2011; 55:1–28.
- Thérond P, Bonnefont-Rousselot D, Davit-Spraul A, Conti M, Legrand A. Biomarkers of oxidative stress: An analytical approach. *Curr Opin Clin Nutr Metab Care*. 2011; 3:373–84.
- Afkarian M, Zelnick LR, Hall YN. Clinical manifestations of kidney disease among US adults with diabetes. *JAMA*. 2016;316(6):602–10.
- Seidah NG, Awan Z, Chretien M. PCSK9: A key modulator of LDL receptors. *Clin Genet*. 2014;85(5):415–23.
- Macchi C, Ferri N, Corsini A. Proprotein Convertase Subtilisin/Kexin Type 9: A multifaceted protein with clinical relevance. *Pharmacol Res*. 2019; 143:11–24.
- Rena G, Hardie DG, Pearson ER. The mechanisms of action of metformin. *Diabetologia*. 2017;60(9):1577–85.
- Thomas MC, Cooper ME, Zimmet P. Changing epidemiology of type 2 diabetes mellitus and associated chronic kidney disease. *Nat Rev Nephrol*. 2015;12(2):73–81.
- Forbes JM, Thorburn DR. Oxidative stress in diabetic kidney disease. *Nat Rev Nephrol*. 2018;14(5):291–312.
- Foretz M, Guigas B, Viollet B. Understanding the glucose-lowering effect of metformin: Mechanisms of action and therapeutic perspectives. *Diabetes Metab*. 2014;40(4):223–9.
- Yang HL, Thiyagarajan V, Shen PC, Huang PJ, Huang HL, Hou WC. Antioxidative and anti-inflammatory effects of metformin in a rat model of diabetic nephropathy. *J Cell Physiol*. 2020;235(2):1242–54.